

**PATIENT**

Tinsel Toes 59953248

**SPECIES**

Feline

**BREED**

DSH

**SEX**

Neutered Male

**AGE**

4 Years

**WEIGHT**

~10 Pounds

**INTERPRETED BY**

Eric Lindquist, DMV,  
DABVP (Canine &  
Feline), Cert. IVUSS

**IMAGING  
PERFORMED BY**

Greg Shaffer

**HOSPITAL NAME**

Saint Frances AC

**REFERRING VET**

Dr. O'Sullivan

**INVOICE**

35324

**DATE**

1/8/26

**PRESENTING CLINICAL SIGNS**

History: Practice scan. immediate post op neuter  
Abnormal PE/Chem/CBC/UA Results: None. Healthy P.

**ULTRASONOGRAPHIC EXAMINATION OF THE ABDOMEN**

**Urinary System**

The **urinary bladder** and visible pelvic urethra were unremarkable for the level of repletion presented. The urine, however, did present some mildly echogenic debris consistent with mucous, exfoliated cells from renal or bladder origin, and/or blood clots as these echogenic changes can all present similarly. This is often related to urinary tract infection but may represent simple evidence of exfoliated debris or sterile inflammation. Cystocentesis, urinalysis, +/- culture would be recommended to rule out and define any UTI. This is a mild change.

The **kidneys** revealed normal size and structure, corticomedullary definition and ratio for this age. The cortices presented largely uniform texture with normal echogenic relationship to liver and spleen. Medullary structure differed distinctly from the cortex and no evidence of pelvic dilation was present. The capsules were acceptably uniform without significant irregularities. The right kidney measured 4.74 cm. The left kidney measured 4.54 cm.

**Adrenal Glands**

The regions of the **adrenal glands** revealed no evident pathology.

**Spleen**

The **spleen** presented a smooth homogeneous parenchyma hyperechoic to liver and renal cortical parenchyma. The capsule was smooth without noticeable expansion or deviation from within the spleen or adjacent pathology. The splenic vasculature demonstrated normal volume without signs of congestion or thrombosis. No sonographic evidence of acute or chronic inflammatory, neoplastic, or infarctual changes were noted.

**Liver**

The **liver** images submitted revealed subjectively normal liver size, contour, and structure. Parenchymal echogenicity was naturally coarse and hypoechoic to the spleen. Vascular and biliary tracts were of normal volume with no evidence of congestion. The gallbladder presented acceptably thin walls with primarily anechoic content. The cystic and common bile ducts were normal. No pathological hepatic lymphadenopathy was evident. No overt structural evidence of inflammatory, infiltrative or regenerative pathology was evident.

**Gastrointestinal**

Examination of the **gastrointestinal tract** revealed a stomach and intestine free of stasis, of normal wall thickness, acceptable curvilinear mural detail, and peristaltic activity. Small and large intestine demonstrated normal luminal chyme and stool consistency respectively. No obstructive or overt infiltrative disease was noted. No associated abnormal lymphatic activity was noted.

**Pancreas**



**PATIENT**

Tinsel Toes 59953248

**SPECIES**

Feline

**BREED**

DSH

**SEX**

Neutered Male

**AGE**

4 Years

**WEIGHT**

~10 Pounds

**INTERPRETED BY**

Eric Lindquist, DMV,  
 DABVP (Canine & Feline), Cert. IVUSS

**IMAGING PERFORMED BY**

Greg Shaffer

**HOSPITAL NAME**

Saint Frances AC

**REFERRING VET**

Dr. O'Sullivan

**INVOICE**

35324

**DATE**

1/8/26

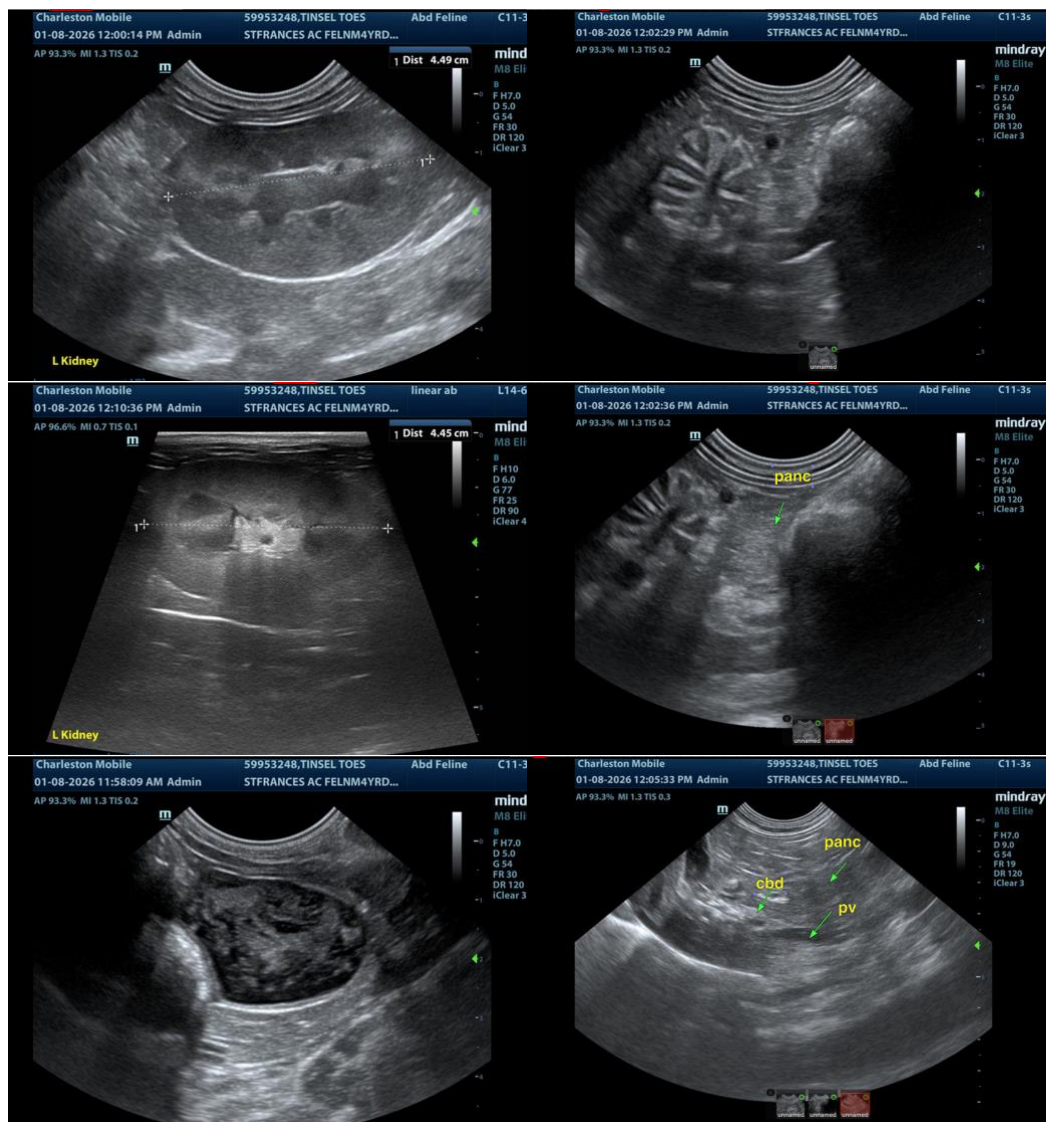
The base and limbs of the **pancreas** were observed to be largely isoechoic to surrounding omental fat. Pancreatic duct and capsular contour were acceptably normal and parenchyma respected normal curvilinear patterns. No overt evidence of active inflammatory or neoplastic disease was noted.

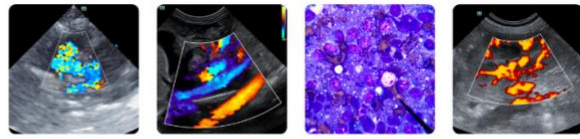
**ULTRASONOGRAPHIC FINDINGS**

- Minor bladder debris
- Structurally unremarkable abdomen otherwise

**INTERPRETATION OF THE FINDINGS & FURTHER RECOMMENDATIONS**

Urinalysis is warranted to assess for evidence of UTI.





**PATIENT**

Tinsel Toes 59953248

**SPECIES**

Feline

**BREED**

DSH

**SEX**

Neutered Male

**AGE**

4 Years

**WEIGHT**

~10 Pounds

**INTERPRETED BY**

Eric Lindquist, DMV,  
 DABVP (Canine & Feline), Cert. IVUSS

**IMAGING PERFORMED BY**

Greg Shaffer

**HOSPITAL NAME**

Saint Frances AC

**REFERRING VET**

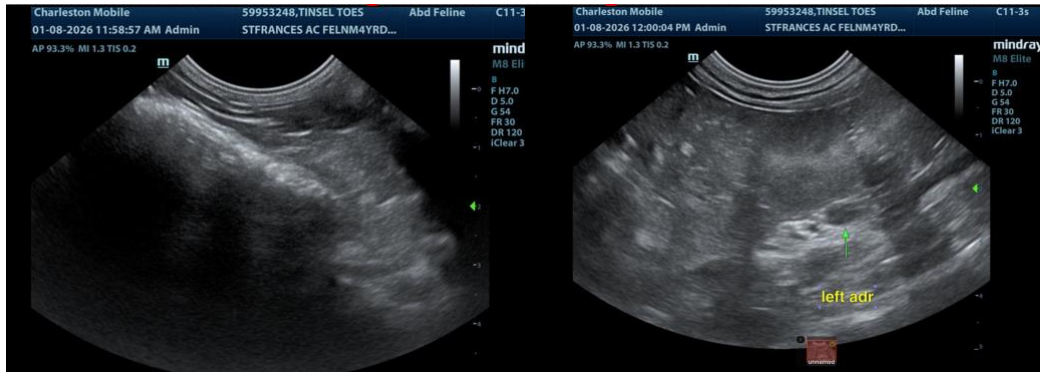
Dr. O'Sullivan

**INVOICE**

35324

**DATE**

1/8/26



The information and recommendations provided are based on the images presented by the referring veterinarian. No evaluation can be communicated regarding pathology that was not visible in the image/video clips provided.

Thank you for this referral. If the clinical or image interpretation does not parallel your findings or if I can be of any further assistance please contact me.

**Eric Lindquist**, DMV, DABVP, Cert. IVUSS, CEO of SonoPath.com

info@SonoPath.com